

[Case Report]

**A 10-YEAR-OLD GIRL WITH IGA NEPHROPATHY WHO 5 YEARS LATER
DEVELOPED THE CHARACTERISTIC FEATURES OF
HENOCH-SCHÖNLEIN PURPURA NEPHRITIS**

MINA CHISHIKI, YUKIHIKO KAWASAKI, MARIKO KANEKO, YUMIKO USHIJIMA,
SHINICHIRO OHARA, YUSAKU ABE, KAZUHIDE SUYAMA,
KOICHI HASHIMOTO and MITSUAKI HOSOYA

Department of Pediatrics, Fukushima Medical University, Fukushima, Japan

(Received May 21, 2010, accepted November 5, 2010)

Abstract : We report a patient who developed Henoch-Schönlein purpura (HSP) 5 years after she presented with immunoglobulin A nephropathy (IgAN). A 10-year-old Japanese female was identified with proteinuria and hematuria by a school urinary screening. The first renal biopsy showed mesangial proliferative glomerulonephritis with immunofluorescent findings consistent with IgAN. She was treated with prednisolone, warfarin, and dilazep dihydrochloride, and the proteinuria and hematuria disappeared 4 months after the onset of treatment. Five years later she developed abdominal pain, gross hematuria and a classic purpuric rash of HSP after acute pharyngitis. The second renal biopsy showed diffuse mesangial proliferation with cellular crescent formation, and the patient was treated with methylprednisolone pulse therapy, prednisolone and mizoribine, resulting in a gradual decrease in urinary protein excretion. Our patient is unusual in that she developed Henoch-Schönlein purpura nephritis 5 years after clinical and biopsy evidence of IgAN, which suggests that IgAN and HSP are different clinical manifestations of the same disease, probably sharing a common pathogenesis.

Key words : HSPN, IgA nephropathy, Pathogenesis, Methylprednisolone, Mizoribine

INTRODUCTION

The relationship between immunoglobulin A nephropathy (IgAN) and Henoch-Schönlein purpura nephritis (HSPN) has long been debated. It has been suggested that these two diseases are different clinical manifestations of the same disease, and probably sharing a common pathogenesis^{1,2)}. Clinical observations supporting this hypothesis include the occurrence of these two diseases in the same family³⁻⁵⁾ and cases of patients presenting with a purpuric rash several years before the development of IgAN⁶⁾. In addition, there have been a few reports of cases of the evolution of IgAN into HSPN.

We describe a 10-year-old girl with IgAN who 5 years later developed the characteristic features of

Henoch-Schönlein purpura (HSP), and review the literature available in English that report additional cases of patients presenting with this combination of symptoms.

CASE REPORT

Proteinuria and hematuria were detected by a school urinary screening in May 2003 when the patient was 10 years of age. The patient was referred to our hospital, where she was admitted. Evaluation on admission disclosed a normal physical examination. Results of laboratory investigations are shown, and laboratory tests revealed a leukocyte count of 7,100/mm³, erythrocyte count 482×10⁴/mm³, platelet count 24.5×10⁴/mm³, serum albumin

知識美奈, 川崎幸彦, 金子真理子, 牛嶋裕美子, 大原信一郎, 阿部優作, 陶山和秀, 橋本浩一, 細矢光亮
Corresponding author : Yukihiro Kawasaki E-mail address : kyuki@fmu.ac.jp
<http://www.jstage.jst.go.jp/browse/fms> <http://fmu.ac.jp/home/lib/F-igaku/>

4.2 g/dl, serum creatinine 0.3 mg/dl, and serum total cholesterol 172 mg/dl. Urinalysis revealed urinary protein excretion of 0.7 g/day, with sediment containing a large number of erythrocytes, 10 leukocytes, and a few granular casts per high-power field. Creatinine clearance (24-hCcr) was 94.2 ml/min per 1.73 m². Immunology studies revealed a serum IgA level of 132 mg/dl, C3 113 mg/dl, C4 17 mg/dl, CH50 31.9 U/ml, antinuclear antibody titer <160 X, and negativity for anti-DNA antibody. The renal biopsy was performed (Fig. 1). Immunofluorescence microscopic examination revealed a predominant deposition of IgA with C3 in the mesangial area. Light microscopic examination showed diffuse mesangial proliferation and a small increase in the mesangial matrix. The patient was diagnosed with IgA nephropathy and was treated with daily oral administration of prednisolone (PSL, initially 1 mg/kg/day), warfarin, and dilazep dihydrochloride. After treatment, the patient's urinary protein excretion decreased and her microhematuria disappeared. The prednisolone treatment was subsequently tapered off after 24 months as the proteinuria and hematuria had completely disappeared. Regular urine analyses did not reveal any abnormalities for

more than 3 years.

In 2008, the patient experienced abdominal pain and palpable purpura on the legs after acute pharyngitis. Two weeks later, hematuria and proteinuria appeared. Subsequently, the proteinuria gradually increased and macrohematuria was appeared. The patient was subsequently referred to our hospital. The results of laboratory tests are shown in Table 1. A diagnosis of HSP was made on the basis of the palpable purpura, abdominal pain, proteinuria, and microhematuria. A second renal biopsy was performed, and immunofluorescence microscopic examination revealed a predominant deposition of IgA with C3 in the mesangial area. Light microscopic examination showed diffuse mesangial proliferation with cellular crescent formation. The patient was, therefore, diagnosed with HSPN of ISKDC grade III, and was treated with three courses of methylprednisolone pulse therapy (1,000 mg/day), followed by daily intravenous administration of PSL (60 mg/day) and mizoribine (MZB, 150mg/day in a single dose). Urinary protein excretion was 3.0–3.5 g/day, gradually decreasing over the following 2 months to less than 0.5 g/day, and the administration of PSL was subsequently

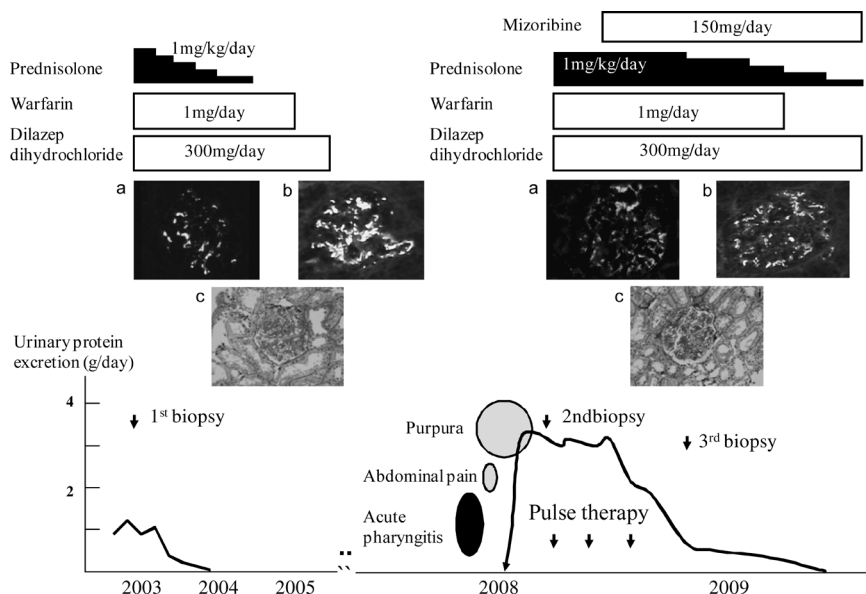


Fig. 1. The clinical course of our patient

- a : IF microscopic examination at the first renal biopsy revealed IgA deposits in the mesangial region. $\times 400$
- b : IF microscopic examination at the first renal biopsy revealed C3 deposits in the mesangial region. $\times 400$
- c : LM revealed diffuse mesangial proliferation and a slight increase in mesangial matrix at the first renal biopsy. PAS stain $\times 400$
- d : IF microscopic examination at the second renal biopsy revealed IgA deposits in the mesangial region. $\times 400$
- e : IF microscopic examination at the second renal biopsy revealed C3 deposits in the mesangial region. $\times 400$
- f : LM revealed diffuse mesangial proliferation with cellular crescent formation at the second renal biopsy. PAS stain $\times 400$

Table 1. Laboratory results at admission (15 years old age)

RBC	445×10 ⁴ /ul	AST	12 IU/l	Na	140 mEq/l	<i>Urination</i>
Hb	13.0 g/dl	ALT	7 IU/l	K	4.3 mEq/l	<u>Urine protein 2.0 g/day</u>
Ht	38.9 %	LDH	144 IU/l	C	108 mEq/l	24Ccr 156 ml/min/1.73 m ²
PLT	22.6×10 ⁴ /ul	ALP	320 IU/l	Ca	9.0 mg/dl	
WBC	7,600 /ul	BUN	9 mg/dl	P	3.1 mg/dl	<i>Sediment</i>
S	0.0 %	Cr	0.39 mg/dl	IgA	183 mg/dl	<u>RBC>100 /HPF</u>
Seg	64.0 %	<u>UA</u>	<u>2.8 mg/dl</u>	C3	105 mg/dl	<u>WBC1-4 /HPF</u>
Mon	6.0 %	TC	172 g/dl	C4	14 mg/d	<u>Cast5-8 /AF</u>
Lym	23.0 %	<u>TP</u>	<u>6.2 g/dl</u>	CH50	30 U/ml	
		ALB	3.7 g/dl	CRP	0.1 mg/dl	
PT	106.3 %	α1-gI	0.19 g/dl	ANA	160>	
APTT	30.3 s	α2-gI	0.60 g/dl	a-DNA ab.	5.0>	
<u>FXIII</u>	<u>57.7 %</u>	β-gI	0.62 g/dl	HBs-Ag	(-)	
		γ-gI	0.94 g/dl	HCV-Ag	(-)	

tapered off to 40 mg/day. During tapering off of the PSL treatment, no purpura or abdominal pain appeared, and urinary protein excretion decreased. In April 2009, a third renal biopsy was performed, and immunofluorescence microscopic examination revealed a small deposition of IgA with C3 in the mesangial area. Light microscopic examination showed slight segmental mesangial cell proliferation and mild mesangial matrix accumulation. None of 26 glomeruli showed any cellular crescent formation. The patient was, therefore, diagnosed with HSPN of ISKDC grade II. The purpura, proteinuria and hematuria all subsequently disappeared, and no proteinuria or purpura was observed during the 6-month follow-up after the discontinuation of PSL administration.

DISCUSSION

HSP is an IgA-mediated immune-complex vasculitis predominantly affecting the skin, joints, gastrointestinal tract, and kidneys. While HSP is often a self-limited condition, approximately 40% of pediatric patients develop nephritis within 4 to 6 weeks of the initial presentation⁷. On the other hand, most patients with IgAN experience persistent microscopic hematuria and intermittent episodes of gross hematuria, usually in association with an upper respiratory infection, with 15-20% of the patients developing either renal failure or hypertension. The diagnosis of IgAN is established by the presence of IgA deposits in the mesangium⁸. Immunologic studies in patients with HSP have revealed what is regarded as a character-

istic feature: the presence of predominantly IgA deposits in the mesangium. The movement of skin and joints together with abdominal symptoms distinguish HSP from IgAN, which usually presents as isolated renal disease.

The possibility of a genetic predisposition to the development of HSP and/or IgAN has been suggested by the many studies on the occurrence of either HSP and/or IgAN within the same families^{5,6,10}. Meadow and Scott reported the interesting evolution of two identical twin brothers who suffered an adenovirus infection at the same time: one of them developed HSP whereas the other presented with only renal manifestations, with the results of a renal biopsy characteristics of IgAN³. There have been occasional reports of the coexistence of HSP and IgAN in different members of the same family. In addition, some patients reported with IgAN had previously presented with bouts of purpuric rash⁶.

Our present case is a 10-year-old girl with IgAN who 5 years later developed the characteristic features of HSP. To date, there has only been one similar case reported, that of a child. We reviewed 4 cases of IgAN that 5 years later developed the characteristic features of HSP and examined the epidemiology and clinical signs of the adults and children involved. These published reports are listed in Table 2. Three patients were male, and one female, and their ages ranged from 10 to 39 (mean 25.5±15.2) years. HSP occurred 2 to 12 (mean 7.2±4.6) years after the onset of IgAN. As to the clinical manifestations of HSP, 4 patients had purpura, 2 had arthralgia, and one had abdominal pain. Two of three patients had high serum IgA levels at

Table 2. Four cases (both adults and children) with IgAN who, 5 years later, developed the characteristic features of HSP

No.	Age (years/sex)	Age of the onset of IgAN (years)	First biopsy	Serum IgA level (mg/dl)		Clinical findings			Second biopsy
				Onset of IgAN	Onset of HSPN	Purpura	Abdominal pain	Arthralgia	
1	10/M	8	+	420	elevated	+	+	-	-
2	38/M	28	+	450	430	+	-	+	+
3	39/M	27	+	-	-	+	-	+	+
4	15/F	10	+	132	183	+	+	-	+

(ourcase)

Patient No. 1 was reported in Hughes *et al.* [8].

Patient No. 2 was reported in Araque *et al.* [12].

Patient No. 3 was reported in Silverstein *et al.* [11].

Patient No. 4 was our case.

the onset of IgAN and HSPN, whereas the serum IgA levels in our case at the onset IgAN and HSPN were within the normal range. These cases, including that reported herein, provide clinical examples of the hypothesis that these IgAN and HSPN are part of a single disease spectrum.

Both HSP and IgAN are likely result from an autoimmune phenomenon. Perturbations in the immune system, including elevations in the serum levels of IgA1 and IgA1-containing, circulating immune complexes have been documented in both HSP and IgAN patients^{13,14}. HSPN is similar to IgAN in that IgA1, but not IgA2, is found in the circulating immune complexes and in mesangial immune deposits¹⁴. The human IgA1 molecule has a hinge region containing up to six O-linked glycan chains consisting of N-acetylgalactosamine (GalNAc), usually with a β -1,3-linked galactose (Gal) attached. The GalNAc and/or Gal may or may not be sialylated, and the Gal-GalNAc disaccharide predominantly exists in its mono- or di-sialylated forms serum IgA1 from normal healthy subjects^{15,16}. As in patients with IgAN, increased galactosedeficient IgA1 (Gd-IgA1) levels have been detected in patients with HSPN, but not in subjects with other glomerular diseases. Gd-IgA1 currently assumes a pivotal role in the pathogenesis of both IgAN and HSPN¹⁷.

The mechanisms of renal injury by the Gd-IgA1 immunocomplex in IgAN and HSPN are as follows: 1) The Gd-IgA1 immunocomplex in the mesangial areas activates a complement pathway, such as the alternative and lectine pathways¹⁸. Hisano *et al.* found that complement activation through the lectine pathway may contribute to the

development of advanced glomerular injuries and prolonged urinary abnormalities in patients with HSPN^{19,20}. 2) The Gd-IgA1 immunocomplex in the mesangial areas activates mesangial cells, which results in cell proliferation, and inflammatory and profibrogenic cytokine and chemokine production, suggesting a pivotal role in mesangial cell proliferation, matrix expansion, and inflammatory cell recruitment²¹.

Our patient is unusual in that she developed HSPN 5 years after clinical and biopsy evidence of IgAN, which suggests that IgAN and HSP are different clinical manifestations of the same disease, probably sharing a common pathogenesis.

REFERENCES

1. Egido J, Sancho J, Mampaso F, Lopez Trascasa M, Sanchez Crespo M, Blasco R, Hernando L. A possible common pathogenesis of the mesangial IgA glomerulonephritis in patients with Berger's disease and Schönlein-Henoch syndrome. *Proc Eur Dial Transplant Assoc*, **17**: 660-666, 1980.
2. Waldo FB. Henoch-Schönlein purpura the systemic form of IgA nephropathy? *Am J Kidney Dis*, **12**: 375-377, 1988.
3. Meadow SR, Scott DG. Henoch-Schönlein syndrome without the rash. *J Pediatric*, **106**: 27-32, 1985.
4. Levy M. French cooperative group of the society of nephrology: Familial cases of Berger's disease and anaphylactoid purpura: More frequent than previously thought. *Am J Med*, **87**: 246-248, 1989.
5. Montoliu J, Lens X, Torras A, Revert L. Henoch-Schönlein purpura and IgA nephropathy in father

- and son. *Nephron*, **54** : 77-79, 1990.
6. Thorner PS, Farine M, Arbus GS, Poucell S, Baumal R. IgA nephropathy : Henoch-Schönlein purpura and Berger's disease in one patient. *Int J Pediatr Nephrol*, **7** : 131-136, 1986.
 7. Haycock GB. The nephritis of Henoch-Schönlein purpura. *In* : Cameron JS, ed. *Oxford Textbook of Nephrology*. 2nd edn. Oxford University Press, Oxford, 585-612, 1998.
 8. Hughes FI, Wolfish NM, McDaine PN. Henoch-Schönlein purpura syndrome and IgA nephropathy : A case report suggesting a common pathogenesis. *Pediatr Nephrol*, **2** : 389-392, 1988.
 9. Yoshikawa N, Ito H, Yoshiya K, Nakahara C, Yoshiara S, Hasegawa O, Matsuyama S, Matsuo T. Henoch-Schoenlein nephritis and IgA nephropathy in children : a comparison of clinical course. *Clin Nephrol*, **27** : 33-237, 1987.
 10. Miyagawa S, Dohi K, Hanatani M, Yamanaka F, Okuchi T, Sakamoto K, Ishikawa H. Anaphylactoid purpura and familial IgA nephropathy. *Am J Med*, **86** : 340-342, 1989.
 11. Silverstein DM, Greifer I, Folkert V, Bennett B, Corey HE, Spitzer A. Sequential occurrence of IgA nephropathy and Henoch-Schönlein purpura : support for common pathogenesis. *Pediatr Nephrol*, **8** : 752-753, 1994.
 12. Araque A, Sanchez R, Alamo C, Torres N, Praga M. Evolution of immunoglobulin A nephropathy into Henoch-Schönlein purpura in an adult patient. *Am J Kidney Dis*, **25** : 340-342, 1995.
 13. Davin JC, Ten Berge IJ, Weening JJ. What is the difference between IgA nephropathy and Henoch-Schönlein purpura nephritis? *Kidney Int*, **59** : 823-834, 2001.
 14. Coppo, Basolo B, Piccoli G, Mazzucco G, Bulzoni MR, Roccatello D, De Marchi M, Carbonara AO, Barbiano di Belgiojoso G. IgA1 and IgA2 immune complexes in primary IgA nephropathy and Henoch-Schönlein nephritis. *Clin Exp Immunol*, **57** : 583-590, 1984.
 15. Renfrow MB, MacKay CL, Chalmers MJ, Julian BA, Mestecky J, Kilian M, Poulsen K, Emmett MR, Marshall AG, Novak J. Analysis of O-glycan heterogeneity in IgA1 myeloma proteins by fourier transform ion cyclotron resonance mass spectrometry : Implications for IgA nephropathy. *Anal Bioanal Chem*, **389** : 1397-1407, 2007.
 16. Novak J, Tomana M, Kilian M, Coward L, Kulhavy R, Barnes S, Mestecky J. Heterogeneity of O-glycosylation in the hinge region of human IgA1. *Mol Immunol*, **37** : 1047-1056, 2000.
 17. Lau KK, Wyatt RJ, Moldoveanu Z, Tomana M, Julian BA, Hogg RJ, Lee JY, Huang WQ, Mestecky J, Novak J. Serum levels of galactose-deficient IgA in children with IgA nephropathy and Henoch-Schönlein purpura. *Pediatr Nephrol*, **22** : 2067-2072, 2007.
 18. Oortwijn BD, Eijgenraam JW, Rastaldi MP, Roos A, Daha MR, van Kooten C. The role of secretory IgA and complement in IgA nephropathy. *Semin Nephrol*, **28** : 58-65, 2008.
 19. Endo M, Ohi H, Ohsawa I, Fujita T, Matsushita M. Complement activation through the lectin pathway in patients with Henoch-Schönlein purpura nephritis. *Am J Kidney Dis*, **35** : 401-407, 2000.
 20. Hisano S, Matsushita M, Fujita T, Iwasaki H. Activation of the lectin complement pathway in Henoch-Schönlein purpura nephritis. *Am J Kidney Dis*, **45** : 295-302, 2005.
 21. Moura IC, Benhamou M, Launay P, Vrtovsnik F, Blank U, Monteiro RC. The glomerular response to IgA deposition in IgA nephropathy. *Semin Nephrol*, **28** : 88-95, 2008.