

[Case Report]

A CASE OF PRIMARY MALIGNANT LYMPHOMA OF THE BREAST WITH AN UNUSUAL ULTRASOUND IMAGE

MASAMI MATSUZAKI¹⁾, TADASHI NOMIZU¹⁾, NAOTO KATAGATA¹⁾,
TAKESHI SAKUMA¹⁾, TOMOYUKI MOMMA²⁾, KAZUNOSHIN TACHIBANA²⁾,
JIN ANDOH²⁾, FUMIAKI WATANABE¹⁾, YOSHIKO YAMAGUCHI³⁾
and MITSUHIRO NIHEI⁴⁾

¹⁾Department of Surgery, Hoshi General Hospital, ²⁾Department of Organ Regulatory Surgery, Fukushima Medical University School of Medicine, ³⁾Department of Pathology, Hoshi General Hospital, ⁴⁾Igarashi medical and surgical clinic

(Received June 11, 2010, accepted October 8, 2010)

Abstract : The patient was a 50-year-old woman with a palpable tumor and pain in the right breast in May of 2008. The tumor was then diagnosed as an atheroma. The tumor enlarged rapidly in June, and the pain and the redness had worsened. The patient was then referred to our hospital. The tumor was in the upper inner quadrant of the right breast with surface redness, measuring about 3 cm. In the mammographic (MMG) findings, the tumor shadow was in the upper inner quadrant of the right breast and was observed to be circular and have a high density with a plain boundary and slightly roughed edges. In the ultrasonographic (US) findings, an oval-shaped high echoic region was found subcutaneously in the right breast. Because the high echoic area was subdivided in the partition of the low echoic string, it looked like a pebbled wall. Upon core needle biopsy, this case was diagnosed as malignant lymphoma. After comparing the histopathology and the US image, it was determined that the pebbled wall-shaped image was due to lymphocyte infiltration of the tissue. The US image was peculiar and we report this case as a peculiar example of malignant lymphoma.

Key words : Malignant lymphoma, High echoic mass, Breast neoplasm

INTRODUCTION

Primary malignant lymphoma of the breast is extremely rare and represents only 0.04 to 0.5% of the malignant neoplasms of the breast¹⁻³⁾. The disease is often difficult to diagnose because there are few reference images with which to compare ultrasounds. In this study, we report a case of malignant lymphoma presenting as an unusual ultrasound image.

CASE REPORT

A 50-year-old woman complained of a palpable

right breast mass and breast pain in May 2008. She visited a local clinic and was treated conservatively under the diagnosis of atheroma. The tumor began growing rapidly in June. She was referred to our hospital for worsening redness and pain. The palpable tumor presented with skin swelling and redness in the upper inner quadrant of the right breast and measured 3 cm in diameter. The tumor was elastic and hard and was fixed to the skin rather than the chest wall. Axillary lymph nodes and other superficial lymph nodes were not palpable. The liver and spleen were also not palpable. The patient did not have a fever, weight loss or night sweats, the so-called B symptoms of lymphoma⁴⁾.

松崎正實, 野水 整, 片方直人, 佐久間威之, 門馬智之, 立花和之進, 安藤 仁, 渡辺文明, 山口佳子, 二瓶光博
Corresponding author : Masami Matsuzaki E-mail address : m.matsuzaki@hoshipital.or.jp
<http://www.jstage.jst.go.jp/browse/fms> <http://fmu.ac.jp/home/lib/F-igaku/>

Hematological examination showed mild anemia (Hb 11.3 g/dl). Four breast cancer-associated tumor markers (CEA, CA15-3, NCC-ST-439 and 1-CTP) were normal. Soluble interleukin-2 receptor (sIL-2R) levels were high at 837 U/ml.

Mammography: There was a high-density mass shadow with microcalcification, which margin was clear, in the upper inner quadrant of the right breast (Fig. 1).

Ultrasonography: Ultrasonography demonstrated a tumorous area that looked like a pebbled wall made a high-echoic ovals located 5 cm from the nipple inside the right breast. In the bottom portion of the pebbled wall-shaped image, there were low-echoic areas (Fig. 2).

Computed Tomography: The tumor was strongly enhanced above the inner right breast. The oval mass had an unclear border with respect to the skin, but had a clear border with respect to the fascia. No metastatic lesions were found in other organs (Fig. 3).

Gallium scintigraphy: Gallium only accumulated in the lesions of right breast. A needle biopsy of suspected breast cancer from these findings was performed. After needle biopsy, malignant lymphoma was the suspected diagnosis. The patient underwent a right lumpectomy for diagnostic purposes.

Histological examination: The tumor was 35 × 22 mm in size. Infiltration of large and somewhat

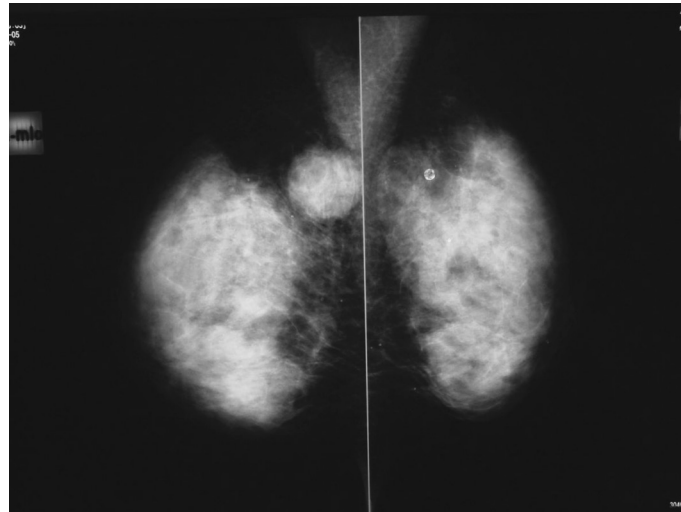


Fig. 1. Mammography (MLO)

A high, coarse, round concentrations was observed in the right upper area of the mammographic image.

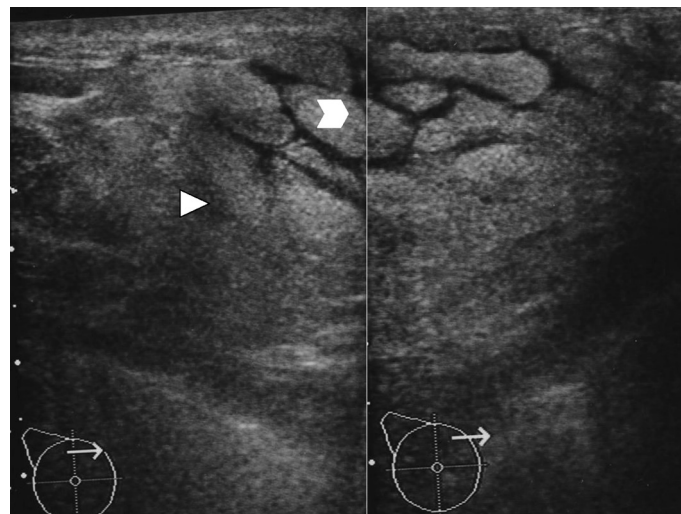


Fig. 2. Ultrasonography

The oval-shaped hyperechoic area just below the skin of the upper inner quadrant of the right breast was separated by the partition of a hypoechoic cord. The non-mass lesion resembled a stone wall.

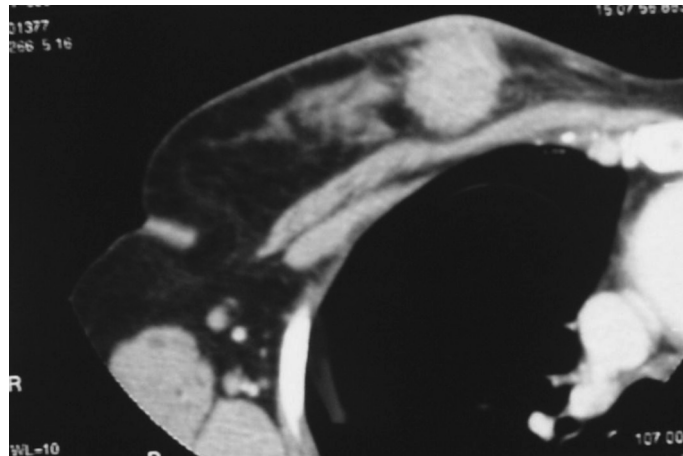


Fig. 3. Computed Tomography
CT demonstrated a round mass that is strongly enhanced inside the upper right breast. Boundaries are unclear in reference to the skin.

irregular lymphoma cells into the adipose tissue surrounding the breast tissue was observed. In non-tumor tissue, small lymphocytic infiltrations were seen around the breast tissue. Tumor cell invasion reached the dermis layer of the skin.

Immunohistochemistry : The tumor was CD20 (+), CD79a (+), CD3 (-), CD5 (-), CD10 (-), CD30 (-), CD56 (-), bcl-6 (+), MUM-1 (+), 80%MIB-1+. Based on the new WHO classification, the tumor was classified as diffuse large B-cell lymphoma, not otherwise specified (activated B-cell type).

Postoperative systemic chemotherapy was conducted over a six-month hospital rotation in hematology. Radiation therapy to the remaining breast tissue was done. She is seen in outpatient and is healthy now.

DISCUSSION

Primary malignant lymphoma of the breast should be categorized as an in situ breast tumor if there are malignant lymphocytes present in the mammary gland. According to the diagnostic criteria by Wiseman⁵⁾, this case was diagnosed as primary malignant lymphoma.

It was difficult to make a diagnosis of breast lymphoma because there are few reports of radiological findings characteristic of malignant lymphoma. The imaging findings in cases of this disease reported in Japan in the last six years are shown in Table 1⁶⁻¹⁹⁾. According to these findings, the mammograms of many patients are reported as high-density tumor shadows. The margin of tumor shadow is rough from the smooth, and often has

similar findings such as spiculation or shape with breast cancer.

In ultrasonographic findings malignant lymphoma focus was reported as primarily a lobulated mass with the boundary. The inside image echoed low and was often expressed as a heterogeneous mass. The case presented here is a non-tumor, irregular, high-echoic mass with indistinct borders, and is quite different from all past reports except one case. Only one example of an internal high-echoic region similar to this case has been reported¹²⁾. However, this case was different in the point of having formed the tumor image. Unfortunately, these two cases could not be compared because the actual image was not reported. The ultrasound image of our case, as compared to the pathological magnifier image (Fig. 4), was understood to reflect the lymphocyte cells invading the subcutaneous fat tissue. Fibrous components of the partition wall in fat tissues were represented in the low-echoic image. As a whole, we describe the overall image as resembling a piled stone wall (Fig. 2). In the image the high-echoic area (white arrowhead in Fig. 2) corresponds to the enlarged pathological image (Fig. 5a). We understood that the high-echoic area was a mixture of adipose tissue and lymphocytes. In addition, we understood that the low-echoic area (white triangle Fig. 2) was almost completely composed of small lymphocytes (Fig. 5b). We assumed that the high-echoic reflections were caused by an impedance of the boundary because there was a difference in echo impedance between fat cells and lymphocytes²⁰⁾.

Ultrasound images of another patient with invasive breast cancer showing widespread infiltration of

Table 1. Primary malignant lymphoma of the breast Ultrasonographic findings (from cases reported in Japan).

case	age	MMGfindings			US findings		
		Shape/ Border/density	Tumor size D×W(mm)	Shape	Boundary zone	Internal echoes	Posterior echo
1 ⁶⁾	71	irregular/ indistinct/high density	16×32	irregular	indistinct –	homogeneous, low-echoic	accentuating
2 ⁷⁾	59	-/-/-	60	polygonal	distinct smooth	heterogeneous low-echoic	accentuating
3 ⁸⁾	78	-/-/-	15×25	lobulated	distinct rough	homogeneous low-echoic	no change
4 ⁹⁾	51	-/-/-	140×110	oval	distinct smooth	heterogeneous low-echoic	–
5 ¹⁰⁾	25	-/-/-	100×70	lobulated	distinct smooth	heterogeneous low-echoic	accentuating
6 ¹¹⁾	40's	polygonal/ circumscribed/ high density	rt.56×43	oval	distinct smooth	homogeneous low-echoic	–
7 ¹¹⁾	40's	-/-/-	lt.42×41	oval	distinct smooth	homogeneous low-echoic	–
8 ¹²⁾	72	irregular/ circumscribed/ high density	45	oval	indistinct –	homogeneous high-echoic	–
9 ¹³⁾	66	oval/circumscribed/ high density	100	–	distinct smooth	– low-echoic	–
10 ¹⁴⁾	44	-/-/-	22×18	–	distinct rough	homogeneous low-echoic	–
11 ¹⁵⁾	30	non-enforcement per pregnancy	28×16	lobulated	distinct rough	homogeneous low-echoic	accentuating
12 ¹⁶⁾	77	-/-/-	30	round	distinct smooth	homogeneous low-echoic	accentuating
13 ¹⁷⁾	71	no abnormality	40×40	oval	distinct rough	heterogeneous low-echoic	–
14 ¹⁸⁾	71	oval/ circumscribed/ high density	12×13	round	distinct smooth	homogeneous low-echoic	accentuating
15 ¹⁹⁾	60's	oval/ circumscribed/ high density	20×30	oval	distinct smooth	heterogeneous low-echoic	accentuating

– : Not Finding Report

the subcutaneous tissue from axillar lymph nodes are shown in Figure 6. In this case, there was a similar pebbled wall-like image. We found that the high-echoic and pebbled wall structures, like those in this case, were an extremely unique finding of cell infiltration to the subcutaneous fat tissue. In the future, if we will see the structure of such a pebbled wall, it might be understood that it is permeation of the lymphocyte or the tumor cell through the subcutaneous adipose tissue.

The malignant lymphoma is immediately taken the shape of permeation early by progress, and extends. And, the malignant lymphoma takes the

form of various tumors based on the level and the permeation place of the lymphocytic infiltrate. Therefore, it is thought that this is one of the reasons for the diversity of the image of the malignant lymphoma.

The density of mammography reflected the cell density. In addition, because the ultrasound images strongly reflected the differences in impedance, there should be more emphasis on mixed status between different cell types than the cell density. The images in this case were extremely unusual, and a discrepancy between the images obtained by mammography and ultrasonography was observed.

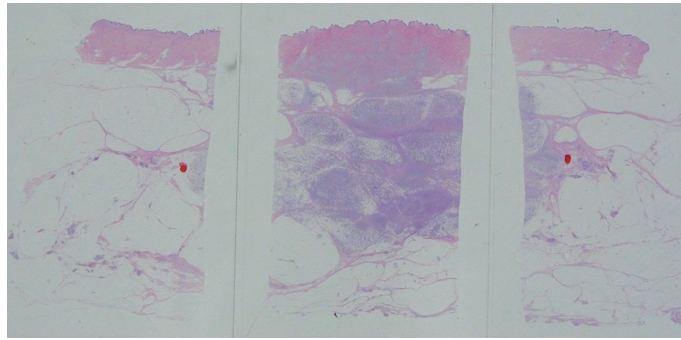


Fig. 4. Histopathological image magnifier
Spotted change was observed in the subcutaneous tissue to match the ultrasound image of stone-like.

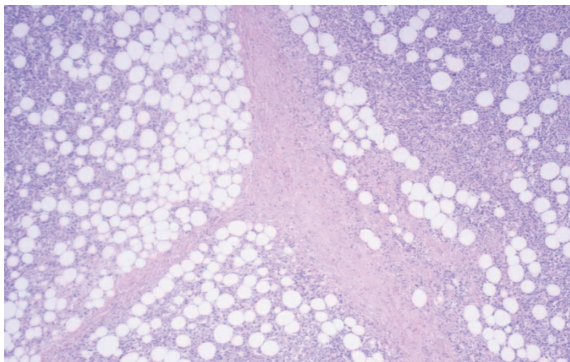


Fig. 5a. Histopathological findings (H & E, 100X)
With lymphocytic infiltration in the subcutaneous fatty tissue, fat cells are mixed with lymphocytes. The fibrous septum was also observed.

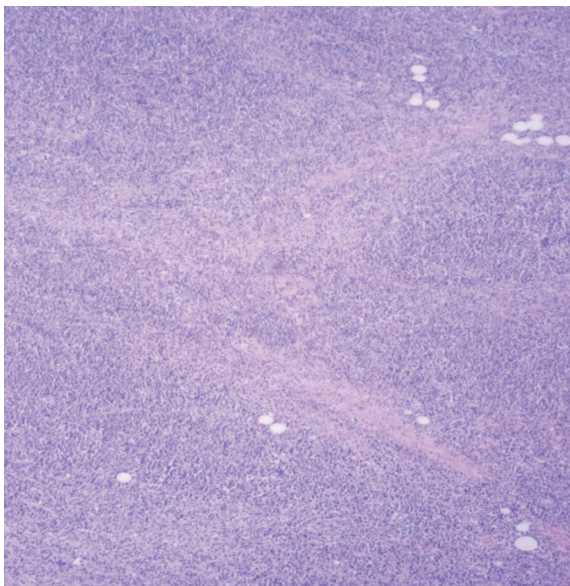


Fig. 5b. Histopathological findings (H & E, 100X)
Most of the fat tissue has been replaced by infiltrating lymphocytes.

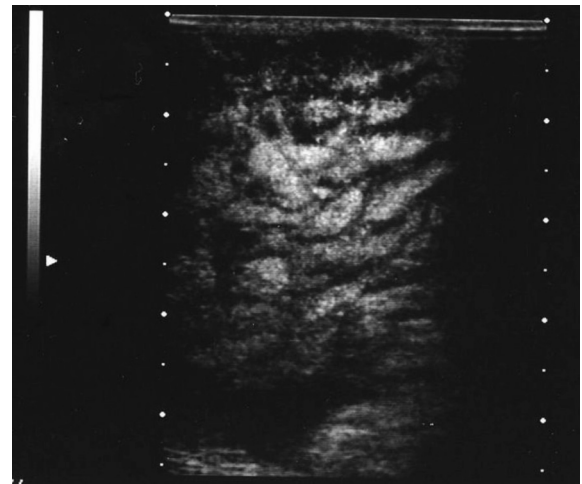


Fig. 6. Ultrasonographic image of another patient
Axillary lymph node metastases of advanced breast cancer revealed subcutaneous infiltration of cancer cells. Ultrasound images revealed the pebbled wall-like pattern.

REFERENCES

1. Freeman C, Berg JW, Culter SJ. Occurrence and prognosis of extra nodal lymphomas. *Cancer*, **29** : 252-260, 1972.
2. Hugh JC, Jackson FI, Hanson J, Poppema S. Primary breast lymphoma An Immunohistologic study of 20 New Cases. *Cancer*, **15** : 2602-2611, 1990.
3. Mambo NC, Burke JS, Butler JJ. Primary malignant lymphomas of the breast. *Cancer*, **39** : 2033-2040, 1977.
4. Guo HY, Zhao XM, Li J, Hu XC. Primary non-Hodgkin's Lymphoma of the breast : eight-year follow-up experience. *Int J Hematol*, **87** : 491-497, 2008.
5. Wieseman C, Liao KT. Primary lymphoma of the breast. *Cancer*, **29** : 1705-1712, 1972.
6. Fuzii M, Takahashi T, Toya M, Furukawa S, Oda T, Hamano K. A case of primary malignant lym-

- phoma of the breast diagnosed after simple mastectomy. *Surgery*, **69** : 1207-1211, 2007.
7. Shiozawa M, Hozumi Y, Nagai H, Sato M, Okumura M, Shinagawa A, Shimokama T. 4 cases of primary malignant lymphoma of the breast. (in Japanese) *Hitachi Medical Journal*, **42** : 40-44, 2003.
 8. Shinohara Y, Shabana M, Hori I, Yoshida M, Ogawa T. Two cases of primary malignant lymphoma of the breast. (in Japanese) *Clinical radiation*, **51** : 644-648, 2006.
 9. Nishimura S, Kosaka K, Yoshikawa K, Kojima T, Ako E, Kinbara I, Yamamoto A, Enomoto J, Yamaki K, Myoutyuu N. An example of breast malignant lymphoma. (in Japanese) *Research and clinical*, **82**(6) : 997-1000, 2005.
 10. Kanemaki Y, Okamoto K, Kurihara Y, Nakajima Y, Fukuda M, Maeda I. A case of primary malignant lymphoma of the breast. (in Japanese) *Nichidoku Iho*, **52** : 282-284, 2007.
 11. Yoshida T, Aono T, Tanaka Y, Nakai S, Yamamoto S, Ogawa T, Morimoto Y, Kurihara Y, Nishikawa K, Syutou Y, Nakamiti I. A case of malignant lymphoma of the breast. (in Japanese) *Osaka Medical General Center Medical Journal*, **26** : 41-43, 2003.
 12. Higa J, Hurukata T, Zyou T, Kenjyo T, Higa U, Yamamoto H, Teruya T, Wakiya R, Isa T, Shiroma H, Aragaki K. A case of primary malignant lymphoma of the breast tumors showed hyperechoic mass. (in Japanese) *Nihon Rinsho Geka Gakkai Zasshi (Journal of Japan Surgical Association)*, **66** : 457, 2005.
 13. Yamaguti M, Kameoka S, Kamio T, Daiti T, Aoyama K, Jibiki N, Miyasaka M. An example of breast malignant lymphoma. (in Japanese) *Nihon Rinsho Geka Gakkai Zasshi (Journal of Japan Surgical Association)*, **87** : 836, 2006.
 14. Katsuno G, Fukunaga S, Tsumura H, Iba T, Sugiyama K, Nagakari K, Kanno M, Sakamoto S, Yoshikawa S, Ito Y, Ohuti M, Kidokoro A. Breast MALT Lymphoma. (in Japanese) *Nihon Rinsho Geka Gakkai Zasshi (Journal of Japan Surgical Association)*, **67** : 596, 2006.
 15. Hirono M, Tanaka K, Ikeda M, Nakajima K, Kurebayashi J, Sonoo H. A case of primary malignant lymphoma of the breast that developed during pregnancy. (in Japanese) *Nihon Rinsho Geka Gakkai Zasshi (Journal of Japan Surgical Association)*, **65** : 900-903, 2004.
 16. Shikishima H, Motohara T, Haseyama H, Kurokawa T, Katoh H, Kaneko Y. A case of primary malignant lymphoma of the breast. (in Japanese) *Clinical breast cancer*, **19** : 157-161, 2004.
 17. Masubuchi S, Sumiyoshi K, Nohara T, Iwamoto M, Tanaka H, Tanikawa Y. A case of malignant lymphoma of the breast. (in Japanese) *Journal of Osaka Medical College*, **67** : 2, 34-38, 2008.
 18. Kobayashi Y, Atsushi S, Kikuti J, Taguti H, Yokoyama S. A case of primary malignant lymphoma of the breast. (in Japanese) *J Jpn Clin Surg*, **64** : 8, 1151-1155, 2009.
 19. Hirose M, Fukuyama Y, Gokan T, Suzuki K, Sawada T, Date Y. A case of primary malignant lymphoma of the breast. (in Japanese) *Nitidoku Iho*, **54** : 2, 228-231, 2009.
 20. Konishi Y. Ultrasonic diagnosis of breast disease (benign and malignant)- tissue diagnosis chiefly. (in Japanese) *Cinical images*, **13**(4) : 362-371, 1997.